

Differential Diagnosis of Stroke in a Setting of High HIV Prevalence in Blantyre, Malawi

J.J. Kumwenda, G. Mateyu, S. Kampondeni, A.P. van Dam, L. van Lieshout and E.E. Zijlstra

Stroke. 2005;36:960-964; originally published online March 31, 2005;

doi: 10.1161/01.STR.0000162585.97216.ef

Stroke is published by the American Heart Association, 7272 Greenville Avenue, Dallas, TX 75231

Copyright © 2005 American Heart Association, Inc. All rights reserved.

Print ISSN: 0039-2499. Online ISSN: 1524-4628

The online version of this article, along with updated information and services, is located on the World Wide Web at:

<http://stroke.ahajournals.org/content/36/5/960>

Permissions: Requests for permissions to reproduce figures, tables, or portions of articles originally published in *Stroke* can be obtained via RightsLink, a service of the Copyright Clearance Center, not the Editorial Office. Once the online version of the published article for which permission is being requested is located, click Request Permissions in the middle column of the Web page under Services. Further information about this process is available in the [Permissions and Rights Question and Answer](#) document.

Reprints: Information about reprints can be found online at:
<http://www.lww.com/reprints>

Subscriptions: Information about subscribing to *Stroke* is online at:
<http://stroke.ahajournals.org/subscriptions/>

Differential Diagnosis of Stroke in a Setting of High HIV Prevalence in Blantyre, Malawi

J.J. Kumwenda; G. Mateyu; S. Kampondeni; A.P. van Dam; L. van Lieshout; E.E. Zijlstra

Background and Purpose—The differential diagnosis of stroke in Africa in areas with high HIV prevalence includes brain infections. We studied causes of stroke in Blantyre, Malawi, where HIV prevalence among medical inpatients is 70%.

Methods—In a descriptive study of 8-month duration, all patients presenting at Queen Elizabeth Central Hospital, Blantyre, with central neurological deficit of acute onset (<24 hours) had baseline investigations, including full blood count, blood glucose, serology for toxoplasmosis, syphilis, and HIV, ECG, echocardiogram, ultrasound of the carotid arteries, and computerized tomography scan of the brain. A lumbar puncture was performed unless contraindicated.

Results—Ninety-eight consecutive patients (49 males) were studied. In those who were HIV positive (48%), the mean age was 37.5 years; ischemic stroke was the commonest diagnosis (n=25; 58%), followed by infection (n=11; 23%; including tuberculous [n=4] and cryptococcal [n=2] meningitis; toxoplasmic encephalitis [n=1]; neurocysticercosis [n=1]; brain abscess [n=1]; and progressive multifocal leucoencephalopathy [n=2]). No clinical or laboratory parameters could be identified as predictors for infection, but 3 of 5 patients with fever on admission had tuberculous meningitis. In HIV-negative patients (mean age 58.6 years), 55% had ischemic stroke and 31% had intracerebral hemorrhage; no brain infection was diagnosed. Presence of vascular disease correlated with age but not with HIV status.

Conclusions—Ischemic stroke was found in half of patients irrespective of HIV status. In those who are HIV positive, brain infection should be considered for which the presence of fever and examination of cerebrospinal fluid seem most useful in diagnosis. (*Stroke*. 2005;36:960-964.)

Key Words: HIV ■ stroke

Among blacks, stroke is more common, more severe, and carries higher mortality when compared with other races; blacks also have increased frequency of risk factors such as diabetes mellitus, hypertension, and obesity.¹⁻³ As in developed countries, stroke is more common in the elderly, but 25% occur in young adults in whom HIV may be a major risk factor.^{1,4} It has been proposed that HIV induces vascular damage: HIV-related coagulopathy by induction of autoantibodies and protein S deficiency has been suggested, whereas other patients were reported to have vasculopathy or vasculitis, either isolated or in the context of meningitis.⁵ The differential diagnosis of stroke in developing countries includes various central nervous system infections (including fungal, bacterial, and tuberculous meningitis [TBM], cerebral toxoplasmosis, neurosyphilis, and neurocysticercosis). Most of these (but not all) are HIV related and may cause a clinical syndrome similar to stroke.⁶

After meningitis, rapid onset focal cerebral deficit is the second commonest disease of the central nervous system among medical patients in Queen Elizabeth Central Hospital (QECH), Blantyre, Malawi, occurring in 2.9% of admissions,

often in young adults (J.J. Kumwenda and E.E. Zijlstra, unpublished observations, 2004). Clearly, it is important to differentiate between stroke and other diagnoses because this influences management. In the medical wards of QECH, 70% of patients are HIV positive, and infections of the central nervous system, in particular cryptococcal, bacterial, and TBM, are common;^{7,8} however, there are no studies to the contribution of (HIV-related) infections to a clinical presentation similar to stroke. We therefore undertook to study the differential diagnosis of stroke in patients admitted to our medical wards.

Materials and Methods

The study was conducted in the medical wards of QECH in Blantyre, Malawi, from October 2001 to July 2002. QECH is the main provider of health care to Blantyre, the largest town in Malawi, and its surrounding district. It provides primary and secondary care and a small range of tertiary care. We aimed to describe 100 consecutive patients admitted with a central neurological deficit clinically thought to be a stroke. Patients were eligible for the study if the central neurological deficit was of sudden onset (<24 hours) without clearly associated trauma, <7 days old, and signs of the deficit could

Received September 28, 2004; final revision received January 22, 2005; accepted February 14, 2005.

From the Department of Medicine (J.J.K., G.M., E.E.Z.), College of Medicine, Blantyre, Malawi; Department of Radiology (S.K.), Queen Elizabeth Central Hospital, Blantyre, Malawi; and Departments of Medical Microbiology (A.P.v.D.) and Parasitology (L.v.L.), Leiden University Medical Centre, Leiden, the Netherlands.

Correspondence to Professor E.E. Zijlstra, Department of Medicine, College of Medicine, Private Bag 360, Chichiri, Blantyre 3, Malawi. E-mail: ee Zijlstra@malawi.net

© 2005 American Heart Association, Inc.

Stroke is available at <http://www.strokeaha.org>

DOI: 10.1161/01.STR.0000162585.97216.ef

be elicited during the assessment. All patients were antiretroviral therapy naive.

A study clinician performed a standardized history and clinical examination. Blood was drawn for full blood count, fasting glucose, syphilis and toxoplasma serology, and HIV test. An ECG was done and examined for arrhythmias and left ventricular hypertrophy (LVH) for which voltage criteria were applied (the greatest amplitude of the S wave in V₁ or V₂ plus the greatest amplitude of the R wave in V₅ or V₆ >35 mm with all amplitudes counted as positive). A plain and enhanced brain computerized tomography (CT) scan, a transthoracic cardiac echo, and a Duplex scan of the carotid arteries were performed soon after admission, but within 1 week. All radiological investigations were done and interpreted by a radiologist (S.K.). Cerebrospinal fluid (CSF) examination was only done in those patients who did not have any contraindication to performing a lumbar puncture.

Laboratory Methods

A full blood count was performed with a Coulter counter. Among HIV-positive patients, the number of individuals with a total lymphocyte count <1400/mm³ was calculated as a surrogate marker for CD4 count.⁹ Blood glucose levels were measured on whole blood using a glucometer. HIV testing was performed using 2 rapid test kits: Determine (Abbott) and Capillus (Trinity Biotech PLC). A patient was diagnosed as HIV infected if both tests were positive. Patients were defined as having AIDS on admission on the basis of the expanded World Health Organization surveillance criteria for AIDS in Africa.¹⁰ Routine examination of CSF (cells, differential count, glucose, protein, Indian ink, gram stain, and culture) was done at the Wellcome Trust Research Laboratories, Blantyre. Serum and CSF samples were shipped to the Leiden University Medical Centre, the Netherlands, in frozen condition. Toxoplasma-specific IgG and IgM were determined by ELFA (VIDAS IgG II TXG; IgM TXM bioMérieux). Treponema pallidum particle agglutination (TPPA) testing (SeroDia; Fujirebio) was done and confirmed by Venereal Disease Research Laboratory testing (Dade-Behring).

After the initial clinical assessment, an attempt was made to arrive at a final diagnosis taking into account the clinical presentation and the results of additional investigations.

Data Management and Analysis

Data were entered and analyzed using the Statistical Package for Social Sciences (SPSS) version 11.0.1. Proportions were compared by χ^2 test and means by Student *t* test. Using multivariate logistic regression, the correlation between age and HIV as independent variables and the occurrence of LVH on the echocardiogram as dependent variable was examined; similarly, clinical features and parameters suggesting infection were examined to their prediction of infection.

Ethical Considerations

Ethical approval was obtained from the College of Medicine Research and Ethics Committee. The patient or a guardian was required to be able to understand and give full informed consent before recruitment. HIV testing was done according to current guidelines at QECH.

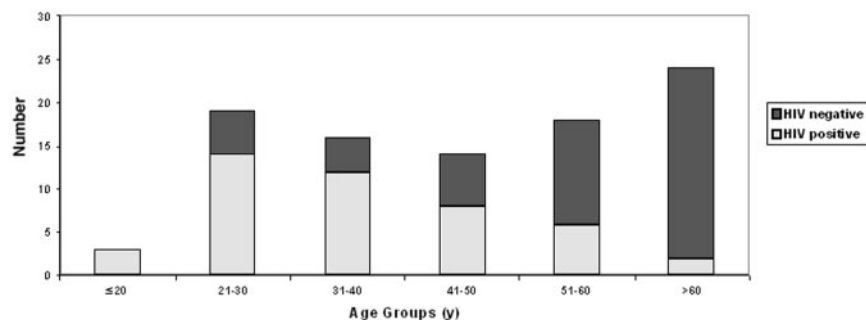
Results

Between October 2001 and July 2002, 100 consecutive patients were enrolled, whereas 11 patients were excluded (8 refused an HIV test and 3 had already recovered on presentation). During analysis, another 2 patients were excluded (duration of deficit >7 days); therefore, 98 patients (49 males) were studied with mean age of 48.5 years (range 16 to 91). Forty-seven patients (48%) were HIV positive with significantly younger mean age than those who were HIV negative (Table). Although HIV-positive females had lower

Comparison According to HIV Status of Sex, Age, Risk Factors, Results of Investigations, Outcome, and Final Diagnosis in 98 Patients Who Presented With a Recent Onset Central Neurological Deficit

	HIV Positive	HIV Negative	<i>P</i>
Male	19	30	
Female	28	21	0.07
Mean age in years (SD)			
All	37.5 (13.1)	58.6 (16.8)	<0.01
Male	42.3 (11.9)	61.2 (17.5)	<0.01
Female	34.3 (13.1)	54.9 (15.5)	<0.01
Lab			
Mean (SD)			
Hemoglobin (g/dL)	11.2 (2.3)	13.7 (2.4)	<0.01
TWC ($\times 10^9/L$)	5.6 (2.7)	7.9 (6.3)	0.03
Platelets ($\times 10^9/L$)	261 (139)	216 (90)	0.06
CT scan			
Normal	9	5	
Infarction	26	27	
Hemorrhage	1	15	
Other	7	2	
Not done	4	2	
Outcome (at discharge)			
Alive, not disabled	7	8	
Alive, disabled	33	36	†
Died	6	7	†
Absconded	1	0	
Final diagnosis			
Had CT scan (n=92)			
Stroke			
Infarction	25	27	0.9
Hemorrhage	1	15	0.001
Infection			
Toxoplasmosis	1	0	
Neurocysticercosis	1	0	
PML	2	0	
TBM	2	0	
Cryptococcal meningitis	2‡	0	
Abscess	1	0	
Other diagnoses			
Brain tumor	1	0	
Subdural hematoma	0	1	
Unknown			
White matter disease	0	1	
Clinical stroke, normal CT	7	5	
No CT scan (n=6)			
TBM	2	0	
Clinical stroke	2	2	

†Not significant; ‡CT scan also showed infarct in 1. TWC indicates total white count.



Distribution in age groups with HIV prevalence in 98 patients admitted with a recent central neurological deficit.

mean age, this difference did not exist between HIV-negative females and males (Table).

The age distribution showed a bimodal pattern with peaks at age group 21 to 30 and >60 years, with HIV prevalence of 74% and 8%, respectively (Figure). Most patients presented within 48 to 72 hours (range 4 to 168), but others presented late, usually because of previous consultation of a traditional healer or other health service providers.

Presenting Symptoms and Physical Findings

Ninety-two patients presented with hemiparesis; the remaining 6 had facial weakness because of a central facial nerve palsy. Aphasia was found in 49%, whereas 16% of patients had convulsions on presentation. Eight patients had a history of fever or were febrile on admission (temperature >37.4°C); all were HIV positive except 1. Meningeal irritation was found in 16% and headache in 51%; there was no correlation with HIV status in either finding.

A history of treatment for hypertension and diabetes mellitus was present in 11% and 2%, respectively (all ≥40 years); 7% and 6% were smokers or used alcohol, respectively (all ≥40 years except 1). There was no significant difference in prevalence of risk factors in relation to HIV status. Twenty-five (53%) HIV-positive patients had AIDS.

CSF Examination

In 59 (60%) patients, CSF was examined. Of 40 patients who had 0 to 5 white cells/mm³, 27 had stroke, 6 had infection, and 7 had another diagnosis. For those with 6 to 100 white cells/mm³, these numbers were 11, 1, and 3, respectively. Four patients (all HIV positive) had >100 white cells/mm³ (range 100 to 1340) with absolute lymphocytosis; 3 were diagnosed as TBM, and 1 had cerebral toxoplasmosis (see below).

ECG, Echocardiography, and Doppler Carotid Scan Findings

Sinus rhythm was found in all ECGs except 1 that showed a third-degree heart block; no patient had atrial fibrillation. Evidence for LVH was found in 36% and 33% for HIV-positive and -negative patients, respectively ($P=0.8$). Trans-thoracic echocardiography showed LVH in 37 (44%); all except 1 were ≥40 years of age. LVH was less common in the HIV-positive group (13 [32%] and 24 [55%] for those HIV positive and negative, respectively, [$P=0.03$]). However, in a logistic regression model, with LVH on echocardiogram as the dependent variable and age and HIV as

independent variables, there was a significant correlation of LVH with age ($P<0.001$) but not with HIV status ($P=0.5$). Four patients had evidence of valvular disease. No vegetations or thrombus was found. Eleven patients had evidence of carotid plaques; all were HIV negative and >50 years of age.

Hematological Findings

HIV-positive patients had lower mean hemoglobin and total white cell count than HIV-negative patients, although this was not found for platelet count (Table). In those who were HIV positive and of whom a total lymphocyte count was available, 14 of 43 (33%) had a total lymphocyte count of <1400/mm³, which predicts a CD4 count <200/mm³ with 73% sensitivity and 88% specificity.⁹

CT Scan Findings

In 6 patients, no CT scan could be done (3 died soon after admission, 1 absconded, and 2 were discharged early). Of 92 CT scans examined, 53 (58%) showed infarcts with equal distribution according to HIV status. The majority of infarcts were localized in the basal ganglia (57%) and the middle cerebral artery territory (28%). Acute parenchymal hemorrhage was found in 16 (17%); all except 1 were HIV negative. All acute hemorrhages were in the thalami and basal ganglia. Nine patients had other findings; in the 7 patients who were HIV positive, these were progressive multifocal leucoencephalopathy (PML; 2 patients) ring-enhancing lesions suggestive of toxoplasmosis, granuloma, abscess, neurocysticercosis, and tumor (1 patient each). In the 2 HIV-negative patients, subdural hematoma and white matter disease of unknown definition were found.

Tuberculous Meningitis

Four (HIV-positive) patients were considered as probable TBM on the basis of a lymphocytic pleiocytosis, high protein and low glucose, and a negative Indian ink test in the CSF examination. Three had a history of fever or were febrile on admission; 2 had meningism.

Cryptococcal Meningitis

All CSF samples were tested by India ink staining; 2 tested positive. In both (HIV-positive) patients, fever and meningeal irritation were absent and the CSF did not show a raised white cell count.

Cerebral Toxoplasmosis

Serum toxoplasma serology was performed on all 98 patients; 21 (9 HIV-positive) patients tested positive. CSF was tested if

serum was positive for antitoxoplasma IgG. One HIV positive patient with probable toxoplasmic encephalitis on CT scan showed a positive result in the CSF.

Neurosyphilis

Of 59 sera that were tested with TPPA, 18 were positive, and 1 had aspecific reactivity. Of these 19, 5 had a positive result in the VDRL test, confirming the presence of syphilis in our population. Of those who tested positive in the serum TPPA, CSF samples were tested. All were negative in the VDRL. Therefore, no cases of neurosyphilis were diagnosed.

PML

Two patients (both HIV positive) were diagnosed with PML based on CT scan findings that included bilateral and asymmetrical low attenuation white matter changes.

Neurocysticercosis

In 2 patients (both HIV positive), the CT scan suggested neurocysticercosis. One had an infarct with parasites appearing in the inactive nodular calcific stage. In this patient, the CSF showed 45 white cells, predominantly lymphocytes. In the other patient, the CT scan showed no additional abnormalities; the CSF was normal.

Final Diagnosis

Ischemic stroke was the commonest diagnosis, irrespective of HIV status (58% and 55% in those HIV positive and negative, respectively). The mean age was 39 years (SD 12.4) and 58.1 years (SD 17.2) for those HIV positive and negative, respectively ($P < 0.001$). In 1 HIV-positive patient in whom the CT scan suggested an infarct, evidence for cryptococcal infection was found (see below). Intracerebral hemorrhage was the second commonest diagnosis occurring mainly in the HIV-negative group (31%) (Table); 9 patients were ≥ 60 years of age, whereas 7 were in age range 35 to 59 years.

Brain infection was found in 11 patients; all were HIV positive: 1 patient had CT scan findings suggestive of cerebral toxoplasmosis that could be confirmed by demonstration of antitoxoplasma IgG in the CSF. One patient had evidence of (concomitant) neurocysticercosis on the CT scan that was otherwise normal. Two patients had confirmed cryptococcal meningitis; 1 of these had a normal scan, and the second had an infarct. Four patients were diagnosed as TBM on the basis of their CSF findings; 2 underwent a CT scan. In 1 of these who was seronegative for toxoplasmosis, the CT scan showed a ring-enhanced granuloma, possibly a tuberculoma; in the other, the CT scan showed brain atrophy. There were 2 cases of PML and 1 cerebral abscess.

Of the 7 HIV-positive patients who had (a history of) fever, 4 had evidence of an infection: 3 TBM and 1 cerebral abscess. And 2 others had an infarct, and 1 had a cerebral tumor. One HIV-negative patient with history of fever had intracerebral hemorrhage. None of the patients with evidence of fever had a raised peripheral total white cell count.

A multivariate logistic regression was done to identify parameters for brain infection; no significant correlations were found for any of the parameters used (history of fever, febrile on admission, age, sex, pulse rate > 100 /min, raised

peripheral white cell count, raised CSF white cell count, lymphocyte count < 1400 cells/mm³, and having AIDS).

Outcome

In-hospital mortality and the proportion of patients with disability on discharge were similar among HIV-positive and HIV-negative patients (Table). The patients with brain infection had the following outcomes. TBM: full recovery after antituberculous treatment and steroids (3) and improved but remained with a neurological deficit (1); cryptococcal meningitis: fully recovered (1) and improved (1) with fluconazol; brain abscess and toxoplasmic encephalitis: fully recovered with appropriate treatment (2); and neurocysticercosis: started on treatment but lost to follow-up (1). The patients with PML (2) were counseled and offered palliative care.

Discussion

Brain infection seems to play an important role in the differential diagnosis of stroke in our setting because evidence for this was found in 23% of HIV-positive patients. In most of these, the infection could explain the clinical presentation. Six patients presented with TBM or cryptococcal meningitis, which are common in our population, with incidence among admitted patients of 8.5 per 1000 and 24 per 1000, respectively (J.J. Kumwenda and E.E. Zijlstra, unpublished observations, 2004). Cerebral infarction has been described as a complication in both conditions.^{11,12} The presence of fever was helpful in diagnosis because 3 of the 4 patients with TBM had a history of fever or were febrile. Although the CT scan features may be suggestive of meningitis or show granulomas, a lumbar puncture is needed. Clinical suspicion of cryptococcal meningitis is more difficult; although severe headache is a common presenting feature in this condition, this was present in 51% of our patients. One patient had evidence for neurocysticercosis (with an otherwise normal CT scan); this condition is uncommon in our setting but is probably underdiagnosed. It may cause vascular damage after arachnoiditis and lead to cerebral infarction;^{13,14} CSF findings did not suggest infection, although this may be influenced by HIV infection, and serological confirmation was not available.¹⁵ One patient was diagnosed as toxoplasmic encephalitis by demonstrating IgG antibodies in serum and CSF; this was confirmed by polymerase chain reaction. PML was found in 2 patients; this condition seems uncommon, most likely because most of our patients probably die before they reach the stage of advanced AIDS. Syphilis, although present in our population, does not seem to play a role in this study.

Probably because of the limited number of patients, no clinical or laboratory parameters could be identified that could reliably predict brain infection from stroke; however, a negative HIV test makes infection unlikely. We only recorded whether clinical features developed within 24 hours; it is possible that patients with brain infection may experience a more gradual onset of symptoms in contrast to those with stroke.

Ischemic stroke was the most common diagnosis in HIV-positive and -negative individuals. All patients with intracerebral hemorrhage were found in the HIV-negative group

except 1. Few stroke patients in our study presented with well-known risk factors, although it is reasonable to assume that in Africa, hypertension is common and is probably severely underdiagnosed, as has been suggested in a recent study from Tanzania.³ Although many of our patients are malnourished and the voltage criteria applied on the ECG may not accurately reflect the presence of LVH, echocardiography suggested that LVH was common in patients ≥ 40 years.

This study suggests that in our setting, there are 2 different clinical entities: in the young age group (20 to 40 years), ischemic stroke is common and occurs in absence of risk factors and evidence of vascular disease. This group has a high HIV positivity rate. In addition, in 23%, evidence for a brain infection is found. In the older age group (> 50 years), infarctions as well as intracerebral hemorrhage are common, and there is evidence of vascular disease in which hypertension may play a role. This group has a low HIV positivity rate and infections were not found. Of course it may be argued that in the young age group, the absence of evidence of vascular disease such as LVH and carotid abnormalities does not exclude hypertension as a possible important risk factor because these features develop with age.

Although data from developed countries confirm HIV infection as a risk factor for stroke,^{16,17} the mechanism is unclear. HIV may cause dilated cardiomyopathy and predispose to meningitis, thus leading to increased prevalence of well-established risk factors such as cardiac embolism and meningitis.^{18,19} Others have suggested HIV induced vasculopathy or a hypercoagulable state.⁵ There is a need for a detailed study of these risk factors among HIV-positive and -negative Africans presenting with stroke. Currently, it is unclear whether in the long term, antiretroviral therapy will modify these risk factors, resulting in lower incidence of stroke in Africa; this issue may be complicated by the effect that certain antiretroviral drugs have on lipid metabolism, which introduces a new risk factor.

In an African setting, brain infection should be considered in HIV-positive patients presenting with stroke, in particular in patients who are febrile. Although some diagnoses require a CT scan, this is not widely available; however, an HIV test and lumbar puncture seem most useful in providing evidence for infection, and these should normally be available in most health facilities.

Acknowledgments

This study received financial support from the Royal Netherlands Embassy, Lusaka, Zambia. We thank the staff of the microbiology department of the Wellcome Trust Research Laboratories for per-

forming the cerebrospinal fluid examination and Helma Hofland for data entry. We are grateful to Dr Will Whiteley for critically reading this article.

References

1. Imam I. Stroke: a review with an African perspective. *Ann Trop Med Parasitol.* 2002;96:435–445.
2. Jones MR, Horner RD, Edwards LJ, Hoff J, Armstrong SB, Smith-Hammond CA, Matchar DB, Oddone EZ. Racial variation in initial stroke severity. *Stroke.* 2000;31:563–567.
3. Walker RW, McLarty DG, Kitange HM, Whiting D, Masuki G, Mtasiwa DM, Machibya H, Unwin N, Alberti KG. Stroke mortality in urban and rural Tanzania. *Lancet.* 2000;355:1684–1687.
4. Hoffmann M, Berger JR, Nath A, Rayens M. Cerebrovascular disease in young, HIV-infected, black Africans in the KwaZulu Natal Province of South Africa. *J Neurovirol.* 2000;6:229–236.
5. Mochan A, Modi M, Modi G. Stroke in black South African HIV-positive patients. *Stroke.* 2003;34:10–15.
6. Pongvarin N. Stroke in the developing world. *Lancet.* 1998;352(suppl 3):19–22.
7. Lewis DK, Callaghan M, Kublin JG, Phiri K, Chipwete J, Borgstein E, Zijlstra EE. Prevalence and indicators of HIV and AIDS among adults admitted to medical and surgical wards in Blantyre, Malawi. *Trans R Soc Trop Med Hyg.* 2003;97:91–96.
8. Gordon SB, Walsh AL, Chaponda M, Gordon MA, Soko D, Mbwvinji M, Molyneux ME, Read RC. Bacterial meningitis in Malawian adults: pneumococcal disease is common, severe, and seasonal. *Clin Infect Dis.* 2000;31:53–57.
9. Kumarasamy N, Mahajan AP, Flanigan TP, Hemalatha R, Mayer KH, Carpenter CC, Thyagarajan SP, Solomon S. Total lymphocyte count (TLC) is a useful tool for the timing of opportunistic infection prophylaxis in India and other resource-constrained countries. *J Acquir Immune Defic Syndr.* 2002;31:378–383.
10. World Health Organization. WHO case definitions for AIDS surveillance in adults and adolescents. *Weekly Epidemiol Rec.* 1994;69:273–275.
11. Poltera AA. Thrombogenic intracranial vasculitis in tuberculous meningitis. A 20 year “post mortem” survey. *Acta Neurol Belg.* 1977;77:12–24.
12. Lan SH, Chang WN, Lu CH, Lui CC, Chang HW. Cerebral infarction in chronic meningitis: a comparison of tuberculous meningitis and cryptococcal meningitis. *QJM.* 2001;94:247–253.
13. Jha S, Kumar V. Neurocysticercosis presenting as stroke. *Neurol India.* 2000;48:391–394.
14. Cantu C, Barinagarrementeria F. Cerebrovascular complications of neurocysticercosis. Clinical and neuroimaging spectrum. *Arch Neurol.* 1996;53:233–239.
15. Hakim JG, Gangaidzo IT, Heyderman RS, Mielke J, Mushangi E, Taziwa A, Robertson VJ, Musvaire P, Mason PR. Impact of HIV infection on meningitis in Harare, Zimbabwe: a prospective study of 406 predominantly adult patients. *AIDS.* 2000;14:1401–1407.
16. Cole JW, Pinto AN, Hebel JR, Buchholz DW, Earley CJ, Johnson CJ, Macko RF, Price TR, Sloan MA, Stern BJ, Wityk RJ, Wozniak MA, Kittner SJ. Acquired immunodeficiency syndrome and the risk of stroke. *Stroke.* 2004;35:51–56.
17. Evers S, Nabavi D, Rahmann A, Heese C, Reichelt, Husstedt IW. Ischemic cerebrovascular events in HIV infection: a cohort study. *Cerebrovasc Dis.* 2003;15:199–205.
18. Cosnett JE. Strokes in young people: experience in a Bantu hospital. *S Afr Med J.* 1969;43:501–507.
19. Bahemuka M. Cerebrovascular accidents (strokes) in young normotensive Africans: a preliminary report of a prospective survey. *East Afr Med J.* 1979;56:661–664.